

Cavernosus muscles contraction during erection: Is it voluntary or reflex, provided the striated nature of the muscles?

Ahmed Shafik, MD, PhD¹

Olfat El Sibai, MD, PhD²

Ali A. Shafik, MCh, MD³

Ismail A. Shafik, MCh, MD⁴

- 1 Professor and Chairman, Department of Surgery and Experimental Research, Faculty of Medicine, Cairo University, Cairo
- 2 Professor and Chairman, Department of Surgery, Faculty of Medicine, Menoufia University, Shebin El-Kom
- 3 Assistant Professor of Surgery, Department of Surgery and Experimental Research, Faculty of Medicine, Cairo University, Cairo
- 4 Lecturer in Surgery, Department of Surgery and Experimental Research, Faculty of Medicine, Cairo University, Cairo

Egypt

Running head: cavernosus muscles contraction during erection.

Abbreviations list

bulbo- and ischio-cavernosus muscles = (BCM, ICM)

intracavernosal pressure = (ICP)

electromyography = (EMG)

corporo-cavernosal reflex = (CCR)

tunica albuginea = (TA)

corpus cavernosum = (CC)

Correspondence:

Ahmed Shafik, MD, PhD

2 Talaat Harb Street

Cairo 11121, Egypt

Phone/Fax: +20-2-749-8851

E-mail: shafik@ahmedshafik.com

www.ahmedshafik.com

(A121-J092-rev)

ABSTRACT

1
2 The bulbo- and ischio-cavernosus muscles (BCM, ICM) contract in the rigid erection phase
3 leading to a suprasystolic cavernosal pressure. We investigated the hypothesis that the
4 contraction of cavernosal muscles is reflexogenic despite their striated nature. The
5 intracavernosal pressure (ICP) and the cavernosus muscles' electromyography (EMG)
6 were recorded in 18 healthy volunteers in the flaccid and erectile phases. The test was
7 repeated after separate anesthetization of the cavernosus muscles and the corpora
8 cavernosa while the penis was in the rigid erection phase. The ICM and BCM showed no
9 EMG activity with tumescence and full erection. When the ICP reached a mean of
10 148.6 ± 9.4 cmH₂O, both the ICM and BCM showed increased EMG activity. The
11 suprasystolic pressure was intermittent and corresponded to the intermittent BCM and ICM
12 contraction. Voluntary cavernosus muscles' contraction did not increase the ICP at the
13 different stages of erection. Anesthetization of the penis in the rigid erection phase led to
14 disappearance of cavernosus muscles' EMG activity, while bland gel application did not.
15 Anesthetization of the 2 contracting cavernosus muscles, while the penis was in the rigid
16 phase, produced an ICP drop to 69.5 ± 7.6 cmH₂O; repetition with saline did not affect the
17 ICP. Cavernosus muscles' contraction on corporal pressure elevation seems to be reflex
18 and mediated through the 'corporo-cavernosal reflex (CCR)'. Changes in the evoked
19 response amplitude would indicate a defect in the reflex pathway.

20 **Key words:** Ischio-/bulbo-cavernosus muscle; corpora cavernosa; intracorporal pressure;
21 electromyography.

INTRODUCTION

22

23 Erection is a complex event regulated by the smooth muscle which composes the
24 cavernous arterioles, venules, and sinusoids (Goldstein & Padma-Natham 1990).
25 Tumescence follows a decrease in corporal smooth muscle tension with a resulting arterial
26 inflow which bathes the cavernous tissues in highly oxygenated arterial blood. Venous
27 outflow is dynamically limited by subtunical venular plexus compression against the tunica
28 7albuginea (TA) (Goldstein & Padma-Natham 1990; Saenz de Tejada et al., 1991). In full
29 erection, the intracavernosal pressure (ICP) increases and can be as high as 85% of the
30 systolic blood pressure (Andersson & Wagner 1995). In the rigid erection phase, the ICP
31 may increase well above the systolic pressure due to ischio- and bulbo-cavernosus (ICM,
32 BCM) muscles' contraction (Andersson & Wagner 1995).

33 The penile bulb is surrounded by the BCM while the penile crura and proximal part of the
34 shaft by the ICM (Skandalakis et al., 2004). The BCM arises from the perineal body and its
35 anterior fibers end in a tendinous expansion which extends over the dorsal aspect of the
36 penis covering the dorsal vessels (Skandalakis et al., 2004). The BCM assists in penile
37 erection by compressing the erectile tissue of the penile bulb and the deep dorsal vein of
38 the penis (Skandalakis et al., 2004; Breza et al., 1989). The ICM arises from the ischial
39 tuberosity and ramus and its fleshy fibers end in an aponeurosis attached to the sides and
40 undersurface of the crus penis (Skandalakis et al., 2004).

41 The ICM and BCM are striated muscles and controlled by somatic nerves (Skandalakis et
42 al., 2004; Breza et al., 1989). During the rigid erection phase, the flow in the internal
43 pudendal artery is almost zero and in the cavernous artery is not measurable (Breza et al.,
44 1989; Lue et al., 1988). The ICM and BCM come into action in the rigid erection phase
45 leading to suprasystolic ICP rise. The suprasystolic pressure is momentary and is
46 transiently achieved during pelvic thrusting. It is not known whether the cavernosus
47 muscles' contraction during the rigid erection phase is induced voluntarily or reflexly.

48 We hypothesized that cavernosus muscles' contraction during the rigid erectile phase is
49 reflexogenic, albeit that the two cavernosus muscles are striated. This hypothesis was
50 investigated in the current study.

MATERIAL and METHODS

51

52 **Subjects.** Eighteen healthy men volunteered for the study. Their mean age was 34.2 ± 5.3
53 SD years (range 26-39). They had no history of urogenital complaint and were sexually
54 active. Physical examination including neurologic was normal. The laboratory workup
55 comprising blood picture, hepatic and renal function tests, and electrocardiogram were
56 unremarkable. The subjects gave an informed consent and the study was approved by the
57 Cairo University Faculty of Medicine Review Board and Ethics Committee.

58 **Methods.** Erection was induced by intracavernosal injection of alprostadil (Lue &
59 Broderick 1998), while the ICP and cavernosus muscles' EMG were being recorded. The
60 effect of cavernosus muscles' contraction on the ICP was registered. Cavernosus
61 muscles' contraction was induced voluntarily and by using electrical stimulation. The ICP
62 was measured by means of 28 gauge needle inserted into the corpus cavernosum (CC) at
63 the middle of the penile shaft. The needle was connected to a strain gauge pressure
64 transducer (Statham 230B, Oxnard, CA, USA) and via amplifiers to a chart recorder
65 (Hewlett-Packard 7798A, Waltham, MA).

66 The electromyographic (EMG) activity of the BCM and ICM was recorded by means of an
67 EMG concentric needle electrode (type 13L49, DISA, Copenhagen) measuring 45 mm in
68 length and 0.65 mm in diameter, introduced into the ischio-cavernosus muscle; the ischial
69 ramus with the overlying crus penis was palpated and the needle inserted into the medial
70 aspect of the ramus. A second identical needle was placed in the bulbo-cavernosus
71 muscle; the bulb of the penis was palpated and the needle electrode introduced into the
72 muscle overlying it. A ground electrode was applied to the thigh.

73 The EMG activity was displayed on the oscilloscope of a standard EMG apparatus (Type
74 MES, Medelec, Woking, UK). Films of the potentials were taken on light sensitive paper
75 (Linagraph type 1895, Kodak) from which measurements of the latency of the reflex and
76 motor unit action potentials were made. The EMG signals were, in addition, stored on an
77 FM tape recorder (Type 7758A, Hewlett-Packard, Waltham, MA, USA) for further analysis
78 as required.

79 The correct position of each needle in the musculature was monitored by the burst of
80 activity heard from the loudspeaker and visualized on the oscilloscopic screen as the
81 muscle was entered. The normality of the myoelectric activity of the 2 cavernosus muscles
82 was tested in all subjects prior to performing the experiment. This was done through

83 muscle stimulation by means of a needle electrode introduced into the relevant muscle
84 and recording the motor unit action potentials by the recording needle electrode. All the
85 subjects had normal EMG activity of the 2 cavernosus muscles. Fine adjustments of the
86 needle position were made while the EMG response to needle insertion was observed on
87 the chart recorder. Multiple recordings were done to assure reproducibility.

88 The ICM and BCM were either electrically stimulated or voluntarily contracted, and the
89 corporal response was recorded in the flaccid and erectile phases. Cavernosus muscles'
90 stimulation was effected by a repeated series of 10 electrical stimuli of 200 μ s duration at a
91 frequency of 0.2 Hz and intensities between 0 and 100 mA. Alprostadil was then injected
92 into the CC and the responses of the ICP, the BCM and the ICM during the different
93 stages of erection were recorded.

94 **Corpora cavernosa and cavernosus muscles' anesthetization.** To test whether the
95 cavernosus muscles' response to ICP elevation was direct or reflex, the 2 cavernosus
96 muscles were anesthetized while the penis was in the rigid erection phase, and the 2
97 muscles were contracting. The muscle anesthetization was effected by injecting 2ml of 1%
98 lidocaine into the muscle bundles around the electrode. The response of the ICP to
99 lidocaine injection of the cavernosus muscles was recorded after 10 minutes of lidocaine
100 injection. The test was repeated by infiltrating the cavernosus muscles with normal saline.

101 On a different day, the CC was anesthetized; the penis was rubbed with lidocaine gel
102 while in the rigid erection phase and while the cavernous muscles were recording
103 increased EMG activity. The ICP response to penile lidocaine rubbing was recorded 10
104 minutes after lidocaine application. The test was repeated using bland gel instead of
105 lidocaine gel.

106 To ensure reproducibility of the results, the tests were repeated at least twice in the
107 individual subject, and the mean value was calculated. The results were analyzed
108 statistically using the Student's t test, and values were given as the mean \pm SD.
109 Significance was ascribed to $p < 0.05$.

110

RESULTS

111 No adverse side effects were encountered during or after the tests were performed, and all
112 the experiments were completed.

113 The BCM and ICM EMG exhibited no resting electric activity. The intracorporal pressure
114 in the flaccid phase recorded a mean of 10.6 ± 1.2 cmH₂O (range 9-12). On cavernosus
115 muscles' stimulation with the aforementioned parameters, they contracted recording a
116 mean amplitude of motor unit action potentials (MUAPs) of 292.3 ± 39.7 μ V (range 216-367)
117 for the ICM (fig. 1) and of 264.5 ± 32.8 μ V (range 186-319) for the BCM (fig. 2). During ICM
118 and BCM stimulation, the ICP did not exhibit a significant change against the basal
119 pressure ($p > 0.05$) (fig. 3), and the penis remained flaccid.

120 During the various phases of erection (latent, tumescent, and fully erected) induced by
121 Alprostadil injection, the ICP increased progressively to reach to a mean of 90.6 ± 10.7
122 cmH₂O (range 76-102) in the full erection phase (table 1). The BCM and ICM EMG
123 showed no activity during the different phases. When the ICP recorded a mean of
124 148.6 ± 9.4 cmH₂O (range 136-162) both the BCM and ICM showed increased EMG activity
125 (fig. 4). The EMG recorded a mean of 221.4 ± 29.6 cmH₂O (range 188-286) for the ICM
126 and 218.4 ± 30.4 cmH₂O (range 172-266) for BCM. The suprasystolic pressure was
127 maintained for a mean period of 73.2 ± 6.1 s (range 50-80) and then dropped to a mean of
128 94.2 ± 11.3 cmH₂O (range 80-108) which did not differ significantly from the pressure during
129 the full erection phase. During the period of the ICP drop to the pre-suprasystolic stage,
130 the ICM and BCM showed no EMG activity. However, after a mean of 18.6 ± 5.2 s (range
131 12-27) the ICP increased to a mean of 137.8 ± 4.4 cmH₂O (range 130-144) and the ICM
132 and BCM to 278.3 ± 36.2 cmH₂O (range 188-312) and 228.4 ± 27.8 cmH₂O (range 157-294),
133 respectively. The increased BCM and ICM EMG activity remained for a mean period of
134 48.2 ± 9.2 sec (range 30-65) after which they showed no activity and the ICP decreased to
135 a mean of 86.2 ± 8.6 cmH₂O (range 66-98). The cavernosus muscles' EMG activity
136 remained silent and the ICP continued to drop until detumescence occurred. When the
137 ICM and BCM were voluntarily contracted while the penis was in the flaccid phase, the ICP
138 did not show a significant change from the basal values ($p > 0.05$). Cavernosus muscles'
139 voluntary contraction during each of the latent, tumescent and fully erected phases
140 effected no significant increase of the ICP. When the subjects were asked to voluntarily
141 contract the cavernosus muscles during the flaccid or erection phases, no significant ICP
142 response was achieved.

143 **Response of the cavernosus muscles to corpus cavernosum anesthetization.** When
144 the penis was rubbed with lidocaine gel while in the rigid erection phase (mean
145 intracavernosal pressure 142.6 ± 10.2 , range 130–156) and with the cavernosus muscles
146 exhibiting increased EMG activity, the muscles myoelectric activity disappeared and the

147 ICP dropped to a mean of 73.6 ± 8.3 cmH₂O (range 62-84). Repetition of the above
148 mentioned test using bland gel instead of lidocaine did not affect the cavernosus muscles'
149 EMG activity. With the 2 cavernosus muscles exhibiting increased EMG activity and the
150 penis in the rigid erection phase, cavernosus muscles' infiltration with lidocaine effected a
151 drop of the ICP to a mean of 69.5 ± 7.6 cmH₂O (range 60-77). Repeating the test using
152 normal saline instead of lidocaine did not affect the ICP.

153 The aforementioned results were reproducible with no significant difference ($p > 0.05$) when
154 the test was repeated in the individual subject.

155

DISCUSSION

156 The current study may shed some light on the role of the cavernosus muscles at erection.
157 Although the number of the studied healthy volunteers was somewhat small (is
158 volunteers), yet it constituted a statistically significant number which seems to be typical of
159 a study of this nature. During erection, the blood gradually fills the caverns of the corporal
160 tissue leading to gradual penile tumescence (Goldstein & Padma-Natham 1990; Saenz de
161 Tejada et al., 1991; Andersson & Wagner 1995). In the flaccid phase, the penis points
162 downward. It gradually elevates with the filling of the cavernous tissue, until it lies
163 horizontally in the full erection phase. Eventually in the rigid erection phase, the penis rises
164 to above the horizontal level and is directed forward with upward inclination. In this
165 position, the penis is presumably perfectly well adapted to its functional performance
166 during the sexual act, as the anatomic direction of the vagina is downward and slightly
167 forward.

168 The mechanism of ICP elevation to the suprasystolic pressure level in the rigid erection
169 phase is not fully elucidated. It could be due to excess blood entrapped in the cavernous
170 tissue (Andersson & Wagner 1995). To what, however, can this extra blood entrapment be
171 attributed? Our current study has revealed that the suprasystolic pressure during erection
172 occurred in episodes associated with increased BCM and ICM EMG activity. This effect
173 most likely confirms that the increased ICP is the result of cavernosus muscles' contraction
174 ((Andersson & Wagner 1995; Fournier et al., 1987; Lavoisier et al 1988). The belt-form
175 cavernosus muscles' insertion into the CC presumably constricts on contraction the dorsal
176 penile vessels, with a resulting extra blood entrapment in the cavernous tissue. It was
177 shown in this study that the increase of the cavernosus muscles' EMG was intermittent,
178 which apparently denotes intermittent cavernosus muscles' contraction. These intermittent
179 muscle contractions seem to be due to the striated nature of the cavernosus muscles.

180 Under normal physiologic conditions, striated muscles continue contraction for a period of
181 50-70 s, after which time they relax spontaneously (Guyton & Hall 1997). Muscle re-
182 contraction may occur after a few seconds.

183 The intermittent cavernosus muscle contraction during rigid erection seems to be
184 advantageous. On cavernosus muscles' contraction, the ICP increases to above the
185 systolic pressure (Andersson & Wagner 1995) and the penile corpora are apparently
186 transmuted into a high-tension closed cavity. Retainment of this high-tension closed cavity
187 for long periods during penile thrusting at coitus may lead to cavernosus tissue ischemia.
188 Therefore, the intermissions in cavernosus muscles' contractions allow for alterations in
189 the periods of muscle contraction and relaxation, during which the cavernous tissue could
190 be well oxygenated, particularly that the periods of cavernosus muscles' contraction are
191 relatively short. These factors provide a natural mechanism that keeps the cavernous
192 tissue well-oxygenated and prevents its destruction by ischemia.

193 **The response of cavernosus muscles to erection with identification of the corporo-**
194 **cavernosal reflex.** The cavernosus muscles' contraction on ICP increase postulates a
195 reflex relation between the two actions. The constancy of this relationship was assured by
196 reproducibility. Meanwhile, the reflex nature of this relationship is evidenced by the
197 absence of suprasystolic pressure response upon anesthetization of the assumed two
198 arms of the reflex arc: the cavernous tissue and the cavernosus muscles. We call this
199 reflex relationship the 'corporo-cavernosal reflex' (CCR). It seems that ICP increase to a
200 certain level stimulates the intracavernosal pressure receptors to send impulses to the
201 spinal cord. These impulses are probably transmitted via the pudendal nerve to the
202 cavernosus muscles effecting their contraction with a resulting increase of the cavernosal
203 pressure. It may be necessary to denote that lidocaine does not block the muscle activity
204 but rather the sensory fibers (C and A α -fibers) which are responsible for pain and reflex
205 activity (Yokoyami et al., 2000; Silva et al., 2002).

206 It appears that the ICP increase to the systolic pressure during erection constitutes the
207 stimulus for activation of the intracavernosal pressure receptors and evoking of the CCR.
208 When, during erection, the ICP reaches a certain level, the CCR is evoked with a resulting
209 cavernosus muscles' contraction, suprasystolic cavernosal pressure elevation and rigid
210 erection. Apparently, this rigid erection improves the quality of the sexual act for both
211 partners as it allows for penile thrusting deep into the vagina, thus augmenting the sexual
212 arousal.

213 In conclusion, cavernosal muscles' contraction on corporal pressure elevation seems to be
214 reflex and mediated through the 'corporo-cavernosal reflex'. Cavernosal muscles'
215 contraction effected ICP increase which apparently leads to rigid erection. Changes in the
216 evoked response amplitude would indicate a defect in the reflex pathway. The CCR might
217 thus act as a diagnostic tool in the investigation of erectile dysfunction; this, however,
218 needs further studies.

219 **Acknowledgment:** Margot Yehia assisted in preparing the manuscript.

REFERENCES

- Andersson KE, Wagner G. Physiology of penile erection. *Physiol Rev* 1995; 75:191-236.
- Breza J, Aboseif SR, Orvis BR, Lue TF, Tanagho EAI. Detailed anatomy of penile neurovascular structures: surgical significance. *J Urol* 1989; 141:437-443.
- Fournier GR, Juenemann KP, Lue TF, Tanagho EA. Mechanisms of venous occlusion during canine penile erection; an anatomic demonstration. *J Urol* 1987; 137: 163-167.
- Goldstein AM, Padma-Natham H. The microarchitecture of the intracavernosal smooth muscle and the cavernosal fibrous skeleton. *J Urol* 1990; 144:1144-1146.
- Guyton AC, Hall JE. Contraction of skeletal muscle. In: 'Human Physiology and Mechanisms of Disease'. Guyton AC, Hall JE (eds). 6th edn, WB Saunders Co, Philadelphia, 1997, pp 59-70.
- Lavoisier P, Proulx J, Courtois F, de Carufel F, Durand LG. Relationship between perineal muscles contractions, penile tumescence and penile rigidity during nocturnal erections. *J Urol* 1988; 139:176-179.
- Lue TF, Broderick G. Evaluation and non-surgical management of erectile dysfunction and priapism. In 'Campbell's Urology', Edrs: Walsh PC, Retik AB, Vaughan ED Jr, Wein AJ. 7th edn. WB Saunders Co, Philadelphia, USA. pp1181-1214, 1998.
- Lue TF, Tanagho EA. Hemodynamics of erection. In: 'Contemporary Management of Impotence and Infertility'. Tanagho EA, Lue TF, McClure RD (eds), 1st edn, Williams & Wilkins, Baltimore, pp 28-38, 1988.
- Saenz de Tejada I, Moronkian P, Tessier J, Kim JJ, Goldstein I, Frohrib D. Trabecular smooth muscle modulates the capacitor function of the penis. Studies on a rabbit model. *Am J Physiol* 1991; 261:H1078-H1085.
- Silva C, Ribeiro MI, Cruz F. The effect of intravesical resiniferatox in patients with idiopathic detrusor instability suggests that involuntary detrusor contractions are triggered by C-fiber input *J Urol* 2002; 168: 575-579.
- Skandalakis JE, Colborn GL, Weidman TA, Badalament RA, Scaljon WM, Parrott TS et al. Male genital system. In: 'Skandalakis Surgical Anatomy. The Embryonic and Anatomic Basis of Modern Surgery'. Skandalakis JE (ed), 1stedn, Paschalidis Medical Publications, Athens, Greece pp 1381-1473, 2004.
- Yokoyami O, Komatso K, Kodama K, Yotsuyanagi S, Nukura S, Namiki M. Diagnostic value of intravesical lidocaine for overactive bladder. *J Urol* 2000; 164: 340-343.

Figure Legends

Fig. 1. Electromyographic activity of the ischiocavernosus muscle.

a) At rest b) On stimulation

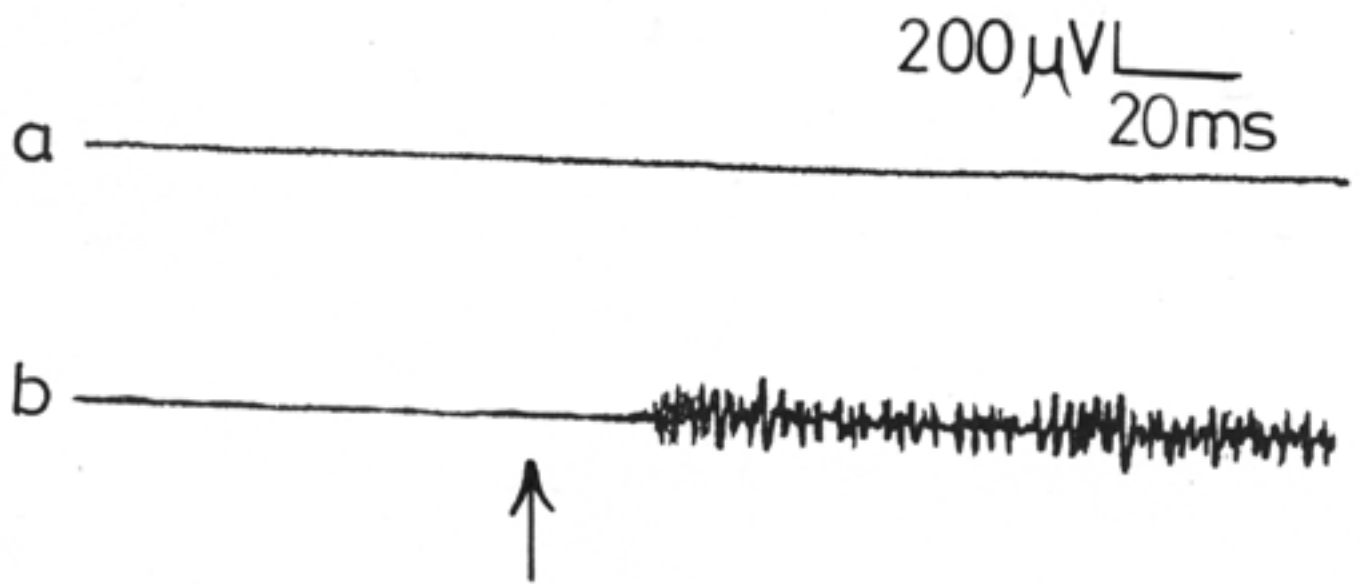
Fig. 2. Electromyographic activity of the bulbocavernosus muscle.

a) At rest b) On stimulation.

Fig. 3. The intracorporal pressure a) at rest and during stimulation of b) ischiocavernosus and c) bulbocavernosus muscles.

Fig. 4. Electromyographic activity of the a) ischiocavernosus and b) bulbocavernosus muscles at an intracorporal pressure of 150 cm H₂O.

↑ = intracorporal pressure of 150 cm H₂O.



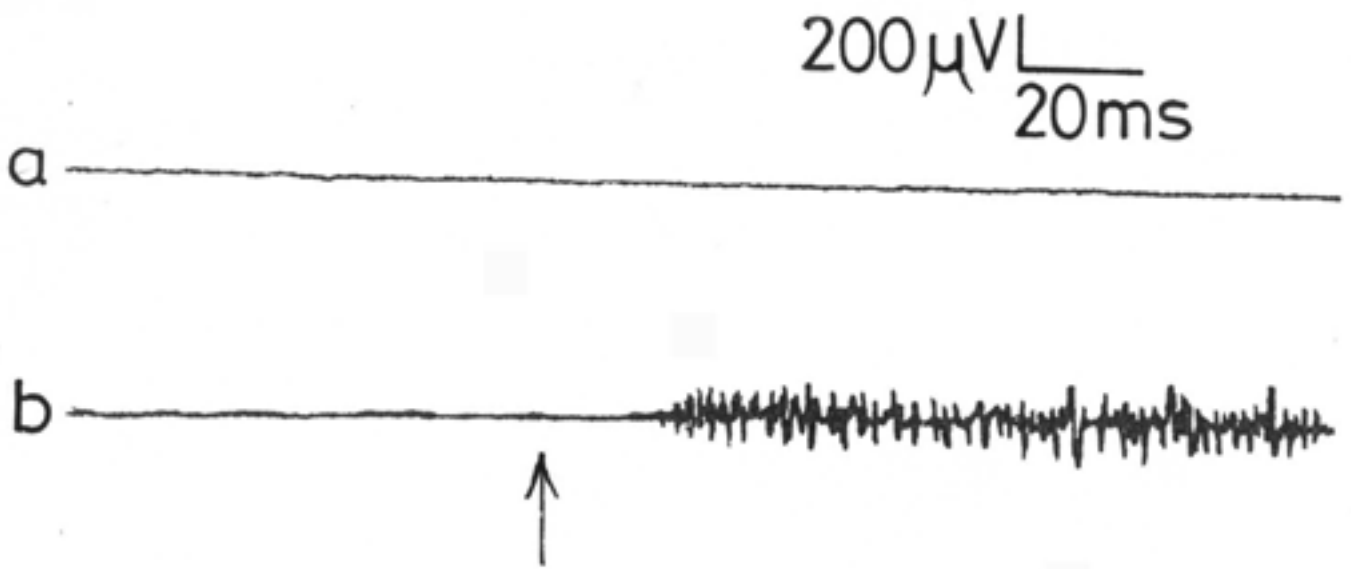


Figure 2

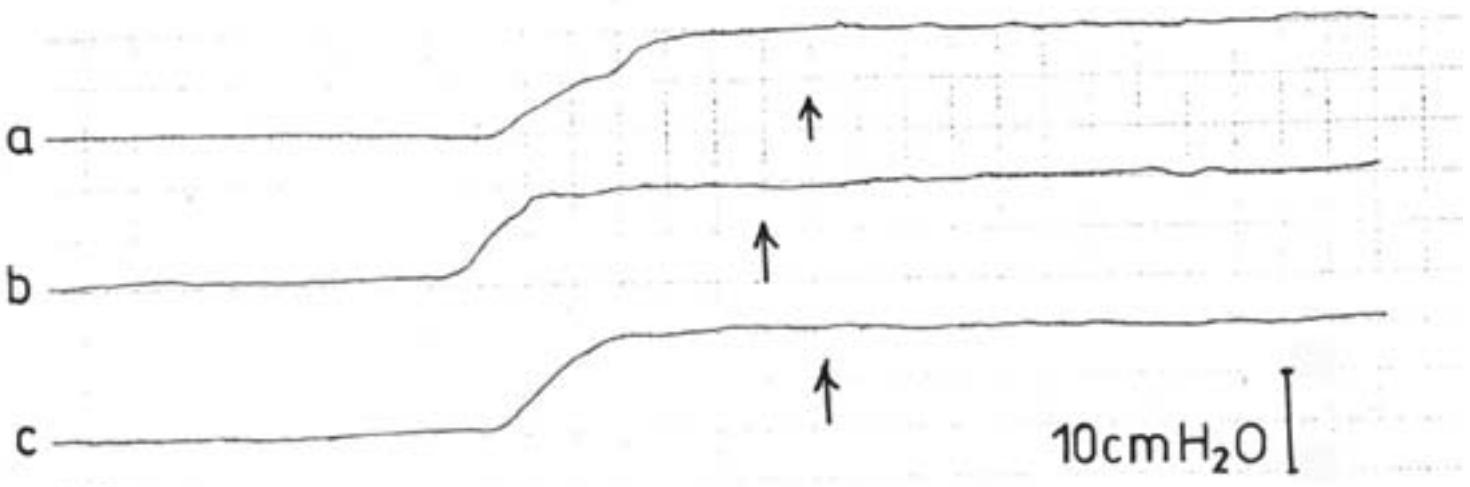


Figure 3

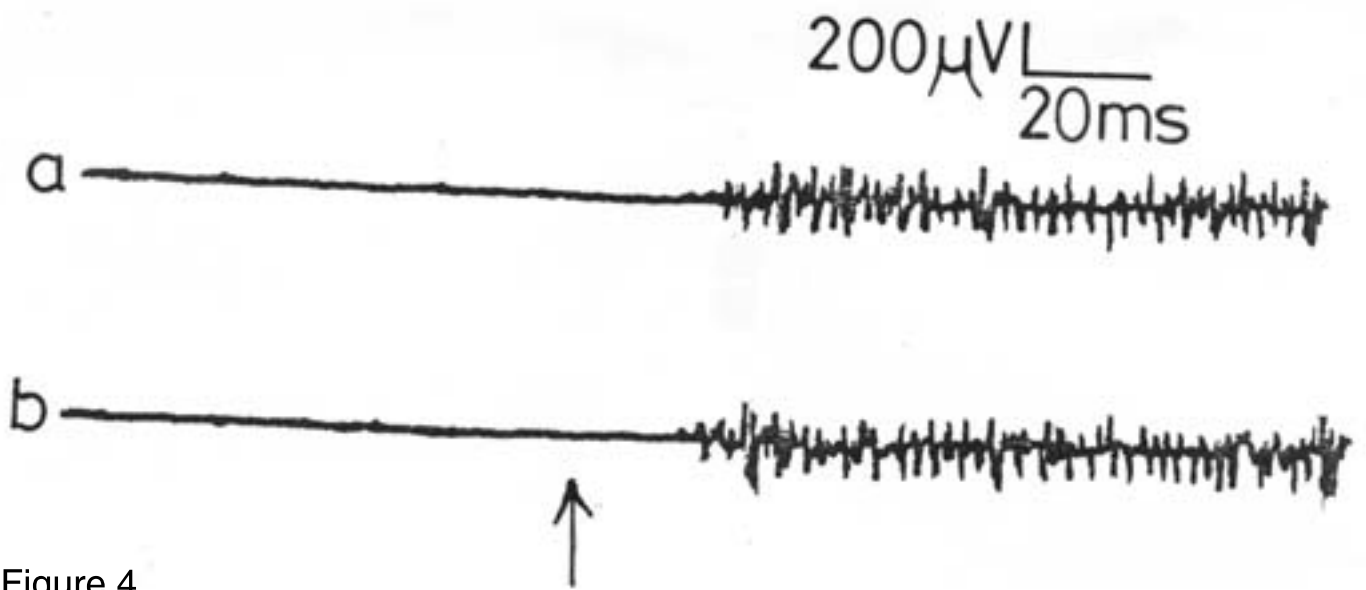


Figure 4

Table 1. The intracavernosus pressure in the different phases of penile erection.

Phases of erection	Pressure (cmH ₂ O)	
	Mean	Range
Flaccid	10.6±1.2	9-12
Latent	56.7±6.8	48-66
Tumescence	71.4±8.3	62-86
Full erection	90.6±10.7	76-102
Rigid erection	148.6±9.4	136-162